

ORIGINAL ARTICLE

## Use of phosphatidylcholine for the correction of lower lid bulging due to prominent fat pads

PATRICK J. TREACY<sup>1</sup> & DAVID J. GOLDBERG<sup>2,3</sup>

<sup>1</sup>Department of Skin Research, Ailesbury Clinic, Dublin, Ireland, <sup>2</sup>Skin Laser & Surgery Specialists of New York and New Jersey, New York, NY, USA, and <sup>3</sup>Department of Dermatology, Mount Sinai School of Medicine, New York, NY, USA

### Abstract

**Background:** Orbital fat tissue, while important in protecting the eye, can protrude during aging, making a patient look 'tired'. Surgical correction, although traditionally the treatment of choice, can lead to scarring. Phosphatidylcholine (PPT) has been shown to reduce the size of these fat pads after direct injection. The compound, licensed in Europe for intravenous treatment of fat embolism, has recently gained interest for reducing localized fat by subcutaneous injection. However, there is a dearth of clinical data relating to efficacy and side effects. **Objective:** An open-label study was conducted in 21 subjects with the goal of reducing the infraorbital fat pad size. The objective of this study was to evaluate the efficacy and safety of PPT after injection into infraorbital fat pads. **Methods:** Twenty-one subjects were injected with 0.4 ml of PPT every 6 weeks to reduce prominent infraorbital fat pads. Pre- and post-treatment digital photographs were taken to document efficacy. In addition, side effects were recorded on a follow-up questionnaire. **Results:** In all, 74% of the subjects showed significant improvement after two to three treatments. Five of the enrolled subjects (23%) were non-responsive after two or more procedures and their treatment was discontinued. None of the patients had adverse side effects other than mild burning, erythema and swelling at the injection site. Nearly every patient maintained the results with no evidence of tissue damage after 6 months. **Conclusion:** PPT injection into infraorbital fat pads resulted in a satisfactory cosmetic effect in most treated subjects. Most subjects required more than one treatment. This simple, office-based treatment provides a non-surgical alternative to patients with prominent infraorbital fat pads. More clinical data are required to fully assess the long-term safety and efficacy of this procedure.

**Key words:** Efficacy, infraorbital fat pads, injection, phosphatidylcholine, safety

### Introduction

The orbital fat tissue plays an important role in protecting the eye and facilitating muscle function. During aging, this subcutaneous and sub-orbicular fat tends to protrude, making the patient look 'tired'. Surgical procedures to correct this problem, although often quite effective, include the risks of scarring and/or scleral show.

It has previously been demonstrated that an injectable lecithin-derived phospholipid called phosphatidylcholine (PPT) can significantly improve the size and appearance of infraorbital fat pad herniation (1,2). PPT is a bile component and is responsible for the emulsification of lipids from the diet (3). PPT is licensed in Europe for intravenous administration for the prophylaxis and treatment of fat embolism (4,5). It has also been employed intravenously in patients

with cardiac ischemia (6) and has previously been used periorbitally in the treatment of xanthelasma (7). More recently there has been a notable clinical interest in the extended use of this novel substance as a means of localized reduction of fat by subcutaneous injection (8,9). Although there has been significant anecdotal experience documenting both the safety and efficacy of this approach, there has also been a dearth of published clinical data relating to side effects after subcutaneous injection. PPT is a natural, well-tolerated, safe pharmaceutical with no significant recorded acute or chronic toxicity, mutagenicity or teratogenicity. The only side effects noted after oral ingestion of high doses are limited to gastrointestinal discomfort (nausea and diarrhea) (10). Preparations of the compound are also safely used in the treatment of premature neonates who are suffering from respiratory distress syndrome (11,12).

Despite a long, documented record of safety, concerns about the cosmetic use of this material remain.

### Objective

The objective of this study was to evaluate the efficacy and safety of PPT after injection into the infraorbital area for the reduction of fat pads. We conducted an open-label study for the treatment of infraorbital fat pad herniation in 21 subjects. Overall goals of the injection were to (i) reduce infraorbital fat pad size; (ii) attempt to create a more refreshed appearance in the upper face; and (iii) establish whether there were any unexpected, prolonged or severe adverse reactions in any of the treated subjects.

### Materials and methods

Twenty-one subjects with varying degrees of infraorbital fat pads were studied. The subjects were randomly selected from patients who had sought treatment for infraorbital fat pads. Subjects receiving anti-coagulant medication were excluded from the study. All subjects were screened for concurrent ocular pathology and were given the choice of blepharoplasty or injectable PPT. Subjects who had undergone previous eye surgery and those who had used retinoids within the previous 6 months were also excluded from the study.

The subject population included 16 women and five men, with ages ranging from 23 to 63 years. Each subject were asked to sign a detailed consent form prior to the procedure and all were aware that the treating pharmaceutical was being used in an unlicensed manner. There were no hematologic or biochemical screens done prior to the procedure. Preoperative evaluation included examining the size and location of the fat pads in order to rule out infraorbital edema. Subjects who were receiving steroids or diclofenic, had known hypersensitivity to soya or lecithin, were suffering from severe renal or hepatic disease, diabetic microangiopathy and autoimmune thyroiditis, and those who were pregnant or lactating were all excluded from treatment.

Standardized baseline photographs were obtained prior to the procedure. Topical anesthesia was applied to the infraorbital areas 15 minutes before the procedure. Gentle pressure over the globe was applied to allow some herniation and better visualization of the fat pad.

Each subject was injected with 0.4 ml of PPT (250 mg/5 ml; bilaterally) into the infraorbital fat pad using a 0.5 ml microfine 30-gauge needle. The technique used included placing 0.2 ml centrally and a further 0.1 ml into both the medial and lateral aspects of the fat pad. The PPT was placed 2 cm below the surface of the skin. Care was taken not to

inject the compound directly into the lacrimal drainage area. The medication was further disseminated by gentle finger massage throughout the fat pad in order to reduce focal effects. Subjects were evaluated for 10 minutes after treatment to evaluate post-treatment swelling. No subjects were given steroids after treatment.

Injections were given at 6-week intervals in order to assess the proper efficacy of PPT. At 6 weeks, subjects were asked to evaluate their improvement based on a rating scale of 0 < 25%, < 50%, < 75% and < 100% of fat pad removal. The number of additional required injections was determined by the physician and/or subject at 6-weekly evaluations. A post-procedural digital photograph was also taken and compared for the effect of treatment. Any side effects that the subject had encountered were recorded on a follow-up questionnaire.

### Results

Most of the subjects (74%) showed improvement after two to three PPT treatments (Figures 1 and 2). Seven (33%) subjects recorded that their improvement was significant (>75%) after just one

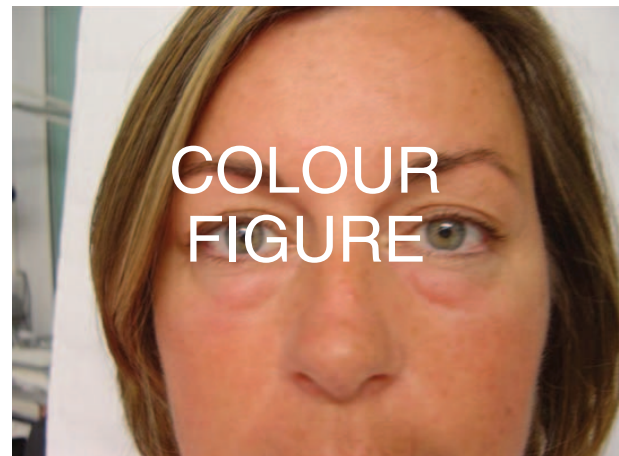

Figure 1. Before phosphatidylcholine injections.



Figure 2. Improvement in lower eyelids after phosphatidylcholine injections.

treatment. Nine (42%) subjects recorded their improvement to be less than 50% after one treatment. However, this increased to >75% after two or more PPT sessions. Five (23%) of the enrolled subjects showed no effective response after two or more procedures and their treatment was discontinued. One of the subjects developed an asymmetrical result, which did not correct despite two further injections into the more prominent side. All of the subjects complained of marked swelling and redness following the injections, which typically lasted about 3–5 days (Figures 3 and 4) This edema and local erythema were noted by all subjects to be substantially less during subsequent injections. Some subjects complained of a mild burning for about 10 minutes post-procedure, but this was minimal in subjects who had effective topical anesthesia. Surprisingly, none of the subjects sustained any bruising despite the location of the injections. No subjects showed any signs of skin infection or tissue necrosis. One subject reported asymmetry in results. However, at 6 months after treatment no recurrences of protruding infraorbital fat pads were noted.




Figure 3. Before phosphatidylcholine injections.

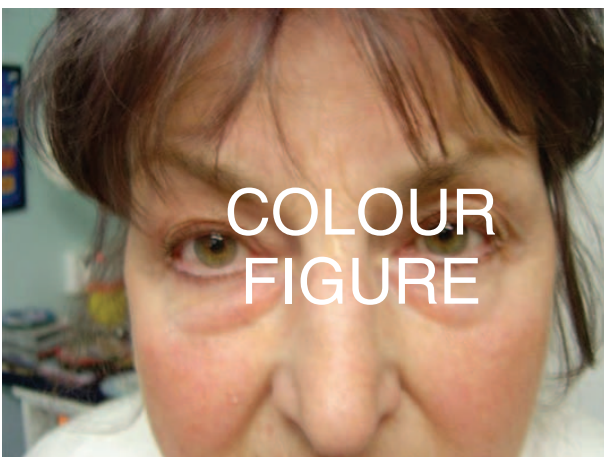

Figure 4. Swelling after phosphatidylcholine injections.

At 6 months, 94% of treated subjects were happy with the overall results. At the 6-month follow-up one subject sought surgery for further improvement.

## Discussion

Prominent infraorbital fat pads are a cause of considerable distress in many people as they tend to make their face look aesthetically 'tired'. During aging, this fat tends to protrude. Surgical procedures to correct this problem have associated risks of scarring and/or scleral show. Many patients desire an office-based treatment for the condition as they do not wish to undergo surgery. Our study confirms the data of others showing that the subcutaneous injection of PPT (250 mg/5 ml) into the fat pads is a simple, non-surgical, office-based procedure that may postpone or even substitute for some instances of lower eyelid blepharoplasty.

Although, PPT has emerged as a safe and efficacious method to reduce small localized fat deposits on other areas of the body (13), it is always necessary to watch for compression of vital retro-orbital structures secondary to bleeding or edema. It is also important for treating physicians to distinguish between infraorbital fat pads and other periocular conditions, including periorbital edema, prominent malar folds and lax lower eyelid skin.

PPT has gained increasing acceptance in both Europe and the USA as a means to achieve a reduction in the volume of smaller fat deposits by means of injections into the subcutaneous fatty tissue (13). PPT has been approved in many countries for the parenteral treatment of hyperlipidemia, peripheral vascular disease, cardiac ischemia, and liver disease. However, in several countries, such as the UK and Ireland, the subcutaneous use of the medication has been criticized (14). This is partly due to a lack of any published collective data regarding safety, and partly due to one manufacturer, including a warning on its medication data sheet stating that it should not be injected by this method. In order to establish some scientific data relating to the subcutaneous use of the medication, a retrospective study of 10 581 patients treated in the UK and Ireland were analyzed for evidence of side effects (14). The treatments had been administered over a mean duration of 13.1 months and localized adverse effects (swelling, erythema, burning/stinging, pain, tenderness and bruising) were rated by most patients as 'very mild' or 'mild'. The total incidence of systemic side effects was very low: Diarrhea, nausea, dizziness/light-headedness and inter-menstrual bleeding were rated by most patients as 'very mild' or 'mild'. There were 15 (0.14%) reported unexpected, severe or prolonged adverse reactions (commonly pain and/or swelling), which were all self-limiting and none judged as serious. The majority of patients (almost 75%) were either 'very satisfied' or 'satisfied' with treatment.

In most Western countries, including the USA, United Kingdom and Ireland, PPT is still used for aesthetic procedures as 'off-label' (13). In Brazil, there have been reports of the misuse of PPT, including the inclusion of unrecognized other substances, beyond the actual PPT, and some severe associated complications when the material was used by non-physicians (9).

The mechanism by which PPT injections dissolve fat in the infraorbital subcutaneous tissue has not been fully established. It is thought that the compound acts as an emulsifying/tensioactive agent after it penetrates the adipocyte through the double lipid layer. This would alter the physical-chemical characteristics of the stored lipids, making them water-soluble (15). An independent review of the phospholipid biochemistry of PPT has recently been published, which aims to deal with some of the issues concerning the pharmacological action of this compound in subcutaneous tissues (16). Further studies are required to determine treatment endpoints and appropriate dosage.

Our study confirms that injection of 0.4 ml (250 mg/5 ml) PPT into the infraorbital fat pads may lead to a reduction in fat herniation with no evidence of residual skin laxity, ectropion or scarring.

## References

- Rittes PG. The use of phosphatidylcholine for correction of lower lid bulging due to prominent fat pads. *Dermatol Surg.* 2001;27:391-2.
- Ablon G, Rotunda AM. Treatment of lower eyelid fat pads using phosphatidylcholine: Clinical trial and review. *Dermatol Surg.* 2004;30:422-7.
- Montgomery R, Conway T. *Bioquímica*. 5th ed. Steele, Paris. 1994. p. 249.
- Kroupa J. The role of pharmacology in the comprehensive prophylaxis of post-traumatic fat embolism. *Acta Chir Orthop Traumatol Cech.* 1993;60:114-22.
- Kroupa J. Lipostabil in the prevention of fat embolism. *Rozhl Chir.* 1966;45:444-52.
- Pogozheva AV, Bobkova SN, Samsonov MA, Vasilév AV. Comparative evaluation of hypolipidemic effects of omega-3 polyunsaturated acids and lipostabil. *Vopr Pitan.* 1996;4:31-37.
- Maggiore S. Phosphatidylcholine for the Treatment of Xanthelasma. Fifth International Meeting of Mesotherapy; 1988, Paris, France.
- Hexsel D, Serra M, Mazzuco R. Phosphatidylcholine in the treatment of localized fat. *J Drugs Dermatol.* 2003;2:511-18.
- URL: [www.network-lipolysis.com](http://www.network-lipolysis.com). Accessed on December 9, 2005.
- Kidd PM. Phosphatidylcholine, a superior protectant against liver damage. *Altern Med Rev.* 1996;1:258-74.
- Zimmermann LJ, Janssen DJ, Tibboel D. Surfactant metabolism in the neonate. *Biol Neonate.* 2005;87:296-307.
- Suresh GK, Soll RF. Overview of surfactant replacement trials. *J Perinatol.* 2005;25(suppl 2):S40-4.
- Hasenschwandtner F. Phosphatidylcholine treatment to induce lipolysis. *J Cosmet Dermatol.* 2005;4:308-10.
- Treacy P. The lipostabil controversy. *Aes Med J.* 2006;6:54-8.
- Palmer M, Curran J, Bowler J. Clinical experience and safety using phosphatidyl choline for the localised reduction of subcutaneous fat. A multicentre retrospective UK study. 2006 (in press).
- Rotunda AM, Suzuki H, Moy RL, Kolodney MS. Detergent effects of sodium deoxycholate are a major feature of an injectable phosphatidylcholine formulation used for localized fat dissolution. *Dermatol Surg.* 2004;30:1001-8.