

ORIGINAL ARTICLE

# Ultrastructural changes seen after ALA-IPL photorejuvenation: A pilot study

ELLEN S. MARMUR<sup>1,2</sup> ROBERT PHELPS<sup>2</sup> & DAVID J. GOLDBERG<sup>1,2</sup>

<sup>1</sup>*Skin Laser & Surgery Specialists of New York and New Jersey, USA, and* <sup>2</sup>*Department of Dermatology, Mount Sinai School of Medicine, New York, NY, USA*

## Abstract

**Background.** Intense pulse light (IPL) treatment currently represents one of the most popular non-ablative photodamage skin treatments. Recent anecdotal evidence suggests that aminolevulonic acid (ALA) photodynamic therapy using IPL as a light source is superior to IPL alone for photorejuvenation.

**Methods.** Seven adult subjects (six women, one man) with minimal photodamage were treated with full face IPL treatment. Half of the face was pre-treated with topical ALA. Pre- and post-treatment biopsies were analyzed for changes in collagen by electron microscopic ultrastructural analysis.

**Results.** An increase in type I collagen fibers was seen after treatment in all subjects. There was a greater increase in type I collagen formation in those subjects who were pre-treated with topical ALA.

**Conclusion.** This small pilot study is the first to focus on the ultrastructural changes seen after ALA-IPL photorejuvenation. We found a greater shift toward type I collagen synthesis in the ALA-IPL group compared to the IPL group. The addition of ALA to IPL treatment for photorejuvenation may be superior to IPL alone.

**Key words:** *Photorejuvenation, ALA-IPL, PDT, photodynamic photorejuvenation, intense pulsed light, photodynamic therapy*

## Introduction

Intense pulse light (IPL) treatment currently represents one of the most popular non-ablative skin treatments. IPL has now been used to treat all aspects of photodamage including early rhytides, skin coarseness, dyschromia, and telangiectasias (16). Unlike conventional ablative treatments, IPL treatment results in significant visible improvement with minimal downtime and a minimal risk of scarring. IPL light sources have also been used for photodynamic therapy in the treatment of actinic keratoses. Recent anecdotal evidence suggests that aminolevulonic acid (ALA) photodynamic therapy using IPL as a light source is superior to IPL alone for photorejuvenation (7).

Intense pulse light is a noncoherent, nonlaser, filtered flashlamp emitting high intensity, broadband visible light (500-1200 nm). Like laser light sources, IPL employs the principle of selective photothermolysis to deliberately heat and destroy target chromophores. Because different structural targets absorb light at different wavelengths, various cut-off

filters can be used to allow a defined wavelength spectrum to penetrate. For example, melanin absorbs throughout the entire visible spectral range (400-750 nm) whereas hemoglobin has several absorption peaks. Using selected filters, IPL therapy can deliver a range of different wavelengths.

Photodamage has now been classified into three categories (8). Type I photodamage includes pigmentary and vascular changes such as lentigenes, telangiectasias, increased skin coarseness, and symptoms of rosacea. Type II photodamage includes structural changes involving the dermis such as the loss of collagen seen with early rhytides. Type III photodamage combines types I and II as well as precancerous actinic keratoses and non-melanoma skin

Table I. Types of photodamage (8).

Type I	Lentigenes, telangiectasias, increased coarseness, symptoms of rosacea
Type II	Rhytides, laxity, dermatochalasis
Type III	Actinic keratoses, seborrheic keratoses, non-melanoma skin cancers

cancers (Table I). IPL, as well as many other treatments, such as topical glycolic acids, retinoids, anti-oxidants, dermabrasion, microdermabrasion, and laser skin resurfacing have been shown to improve photodamage (9-14). All of these modalities address types I and II photodamage. However, there is now early anecdotal evidence that IPL plus ALA photodynamic photorejuvenation may address all three types of photodamage (1).

Topical ALA is a precursor of protoporphyrin-IX (PpIX) in the heme biosynthesis pathway. ALA is preferentially absorbed by rapidly dividing cells in the epidermis and the superficial dermis. PpIX has a maximum absorption at 410, 630, and 690 nm (7) (Figure 1). With light activation, PpIX produces free radicals that cause cellular destruction. This process is called photodynamic therapy and has been FDA cleared for the treatment of actinic keratoses. Currently, topical ALA used in PDT is being studied for the treatment of actinic damage, non-melanoma skin cancer, and moderate to severe acne using 560/1200-nm light sources (15). Therefore, ALA has an established role in the treatment of type III photodamage. This study compared the potential differences in ultrastructural evidence of new collagen formation when one side of the face was treated with IPL alone while the other side was treated with ALA-IPL.

## Materials and methods

Seven adult subjects (six women, one man) with minimal clinical photodamage and minimal erythema, with a mean age of 51 years (ages 34-58 years), and skin phenotypes I-V were included in the study. The entire sun exposed facial skin was treated with IPL (Photoderm VL, Lumenis, Santa Clara, CA), plus right or left side of the face was treated with topical ALA (Levulan, Dusa Pharmaceuticals, Wilmington, MA). Exclusion criteria included a history of photosensitivity reactions, lupus erythematosus, Fitzpatrick skin type VI, or other ablative or nonablative facial procedures within one year.

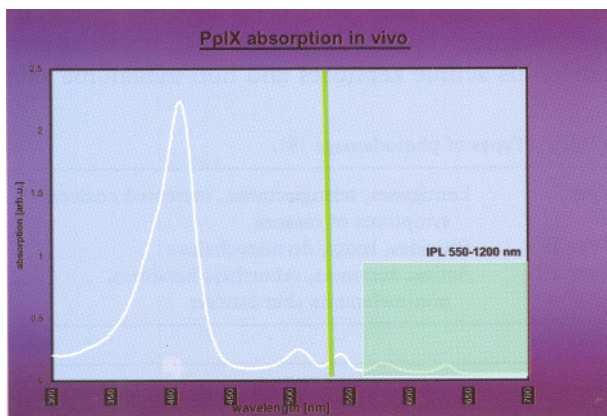


Figure 1. PpIX absorption spectrum.

The study protocol and informed consent were approved by the Investigational Review Committee of Pascack Valley Hospital, Westwood, NJ. Informed consent of all participants was obtained and the study sites were photographed. The patients were randomly assigned to which side (left versus right) of the face would receive treatment with IPL alone versus IPL plus ALA. Two treatments were given at a 1-month interval with follow-up 1 month and 3 months after the second treatment.

ALA was applied to one side of the face 1 hour prior to treatment. A thin layer of transparent gel was used for cooling and skin hydration. Contact cooling ( $-4^{\circ}\text{C}$ ) was provided via incorporation of a cooling chamber head attached to the IPL handpiece.

The subjects' facial skin was irradiated with an intense pulse light source using a 550 nm filter at  $24 \text{ J/cm}^2$ ,  $T_1=2.4 \text{ msec}$ ,  $T_2=6.0 \text{ msec}$  pulse durations, with a 20-30 msec delay. Single passes were carried out over the entire study site. Punch biopsies (2 mm) were taken both before treatment and at 3 months after final treatment for analysis of electron microscopic ultrastructural changes in collagen fibers.

Evaluation of the changes in dermal collagen fiber diameter was undertaken by two independent observers. Electron microscopic sections were evaluated for collagen fiber diameter. Each section was taken at a 1mm depth in the tissue specimen. Ten sections per specimen and ten collagen fibers per section were evaluated using a magnifying loupe. One hundred fibers per specimen were grouped into populations based on size (nm). These were plotted on a graph where the x-axis is collagen fiber size and the y-axis is the number of fibers. Since new collagen is in the form of type III collagen, it is smaller in diameter than type I collagen. A change in size of collagen fibers toward a smaller caliber would indicate early collagen synthesis whereas a change in size of collagen fibers toward a larger caliber would indicate increased type I collagen.

Subjective patient reports and adverse effects were also recorded at each follow-up visit.

## Results

All patients completed pre- and post-treatment biopsies. Ultrastructural analyses showed a shift toward type I collagen in the post-treatment specimens in the IPL group (Figure 2). An even greater shift toward type I collagen is seen in the post-treatment specimens in the ALA-IPL group (Figure 3).

All seven patients reported a subjective improvement in skin quality. In no patients was there a reported difference between the IPL versus the IPL plus ALA study sites.

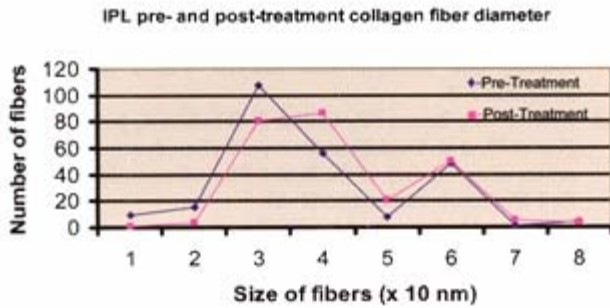


Figure 2. IPL pre- and post-treatment collagen fiber diameter. There is an increase in number of post-treatment type I collagen fibers.

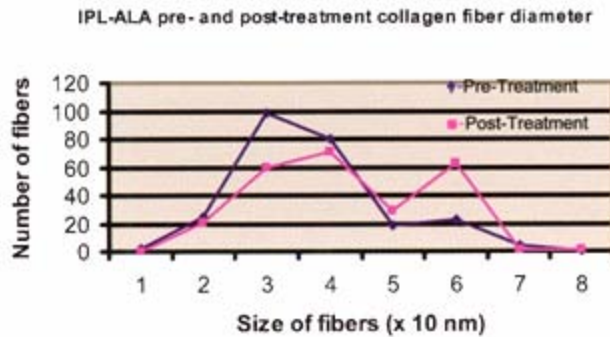


Figure 3. IPL pre- and post-treatment collagen fiber diameter. There is an increase in number of post-treatment type I collagen fibers. The increase is even greater than that seen in the IPL only treated group.

Side effect profiles in this study were minimal. No dyspigmentation, blistering, or crusting occurred. Transient, mild erythema and burning which required no additional therapy and resolved within 24 hours after treatment was reported on both sides of the face.

## Discussion

There is anecdotal evidence that ALA-IPL is superior to IPL alone for facial rejuvenation. In addition, there is strong evidence that IPL causes thermal damage to collagen and stimulates new collagen synthesis, first in the form of type III collagen and collagen precursors that later become cross-linked to form type I collagen (4). The results of this study show a slight shift toward increased type I collagen in the ALA plus IPL group.

Theoretically, thermal damage from IPL plus free radical destruction from ALA-PDT might lead to greater dermal remodeling than from IPL treatment alone. Our results show a trend towards even greater formation of type I collagen when IPL treatment is augmented by the addition of topical ALA. The results may have been much more marked had we chosen subjects with significant actinic damage—a group known to respond well to PDT treatment for actinic keratoses (16).

Whether this trend toward greater type I collagen formation after ALA-IPL treatment will become

statistically significant requires larger scale studies. With only seven subjects, statistical significance in the present small study is difficult to establish. Another limitation in establishing a more dramatic trend may lie in the mechanism of action of ALAPDT. Since ALA is preferentially taken up into rapidly dividing cells of the epidermis and superficial dermis, it requires sufficient actinic damage or metabolic activity to work. An intact stratum corneum inhibits maximum penetration of the ALA into the collagen fibers of the superficial dermis. Our results may reflect the limited ability of the ALA to penetrate significantly into the dermis in patients with only minimal photodamage. This may introduce a selection bias because our study population may have had insufficient actinic damage to benefit maximally from ALA-photodynamic photorejuvenation.

This small pilot study is the first to focus on the ultrastructural changes seen after ALA-IPL photorejuvenation. We found a greater shift toward type I collagen synthesis in the ALA-IPL treatment group compared to the IPL-only treatment group. Our patients reported an overall subjective improvement in the quality of their skin without the adverse effects of more invasive technologies. Future larger studies are required to establish a precise role for the addition of ALA photodynamic therapy in IPL photorejuvenation.

## References

1. Raulin C, Greve B, Grema H. IPL technology: a review. *Lasers Surg Med.* 2003;32:78-87.
2. Bitter PH. Noninvasive rejuvenation of photodamaged skin using serial, full-face intense pulsed light treatments. *Dermatol Surg.* 2000;26:835-43.
3. Bjerring P, Christiansen K. Intense pulsed light source for treatment of small melanocytic nevi and solar lentigines. *J Cutan Laser Ther.* 2000;2:177-81.
4. Goldberg DJ, Samady JA. Intense pulsed light and Nd:YAG laser non-ablative treatment of facial rhytids. *Lasers Surg Med.* 2001;28:141-4.
5. Jessen C, Kuhnen G. No evidence for brain stem cooling during face fanning in humans. *J Appl Physiol.* 1992;72:664-9.
6. Kawada A, Shiraishi H, Asai M, Kameyama H, Sangen Y, Aragane Y, et al. Clinical improvement of solar lentigines and ephelides with an intense pulsed light source. *Dermatol Surg.* 2002;28:504-8.
7. Ruiz-Rodriguez R, Sanz-Sanchez T, Cordoba S. Photodynamic photorejuvenation. *Dermatol Surg.* 2002;28: 742-4.
8. Nestor M GM, Weiss R, Goldberg D, Rigel D. New Perspectives in Photorejuvenation. *Skin & Aging.* 2003;11: 68-74.
9. Gladstone HB, Nguyen SL, Williams R, Ottomeyer T, Wortzman M, Jeffers M, et al. Efficacy of hydroquinone cream (USP 4%) used alone or in combination with salicylic acid peels in improving photodamage on the neck and upper chest. *Dermatol Surg.* 2000;26:333-7.
10. Stiller MJ, Bartolone J, Stern R, Smith S, Kollias N, Gillies R, et al. Topical 8% glycolic acid and 8% L-lactic acid creams for the treatment of photodamaged skin. A double-blind vehicle-controlled clinical trial. *Arch Dermatol.* 1996;132: 6t1-6

11. Piacquadio D, Dobry M, Hunt S, Andree C, Grove G, Hollenbach KA. Short contact 70% glycolic acid peels as a treatment for photodamaged skin. A pilot study. *Dermatol Surg.* 1996;22:449-52.
12. Tan MH, Spencer JM, Pires LM, Ajmeri J, Skover G. The evaluation of aluminum oxide crystal microdermabrasion for photodamage. *Dermatol Surg.* 2001;27:943-9.
13. Kaidbey K, Sutherland B, Bennett P, Warner WG, Barton C, Dennis D, et al. Topical glycolic acid enhances photodamage by ultraviolet light. *Photodermatol Photoimmunol Photomed.* 2003;19:21-7.
14. Prieto VG, Sadick NS, Lloreta J, Nicholson J, Shea CR. Effects of intense pulsed light on sun-damaged human skin, routine, and ultrastructural analysis. *Lasers Surg Med.* 2002;30:82-5.
15. Morton CA, Brown SB, Collins S, Ibbotson S, Jenkinson H, Kurwa H, et al. Guidelines for topical photodynamic therapy: report of a workshop of the British Photo dermatology Group. *Br J Dermatol.* 2002;146:552-67.
16. Goldman M, Atkin D. ALA/PDT in the treatment of actinic keratosis: spot versus confluent therapy. *J Cosmet Laser Ther.* 2003;5:107-10.