

# Laser removal of pigmented and vascular lesions

David J Goldberg, MD, JD<sup>1,2</sup>

<sup>1</sup>Director, Skin Laser & Surgery Specialists of New York and New Jersey, Clinical Professor of Dermatology, Director, Laser Research and Mohs Surgery, Mount Sinai School of Medicine, New York, NY

<sup>2</sup>Adjunct Professor of Law, Fordham Law School, New York, NY

## Summary

Twenty years of laser dermatology has resulted in current technology which allows variable spot sizes, different wavelengths, and a variety of effective cooling devices. These developments have made the treatment of cutaneous pigmented and vascular lesions safe and efficacious by targeting selected chromophores while minimizing damage to the surrounding tissue. Vascular lesions are targeted by a variety of wavelength lasers including the KTP (532 nm), pulsed dye (585–595 nm), and the Nd:YAG (1064 nm) laser systems. Pigmented lesions may be treated with a wide variety of lasers due to the broad absorption spectrum of melanin. Intense pulsed light (IPL), with its widely adjustable parameters, has established itself as a useful adjunctive for the treatment of a variety of pigmented and vascular lesions. The purpose of this review article is to present the current treatment options for the common aesthetic complaints of pigmented and vascular lesions.

*Keywords:* lasers, pigmented lesions, vascular lesions

## Introduction

Anderson and Parrish<sup>1</sup> first introduced the principle of selective photothermolysis, applicable to the laser treatment of cutaneous lesions, in 1983. They postulated that a target could be selectively destroyed, by using the appropriate wavelength, pulse duration and pulse energy.<sup>1</sup> Over the last 20 years this principle has been used to develop the current-day chromophore-specific lasers. The target chromophore in the case of vascular lesions is hemoglobin in its various states; for pigmented lesions it is the melanosome (Fig. 1).<sup>2</sup>

## Lasers for pigmented lesions

Q-switched mode lasers, with pulse durations shorter than the thermal relaxation time (TRT) of melanosomes, adhere to the theory of selective photothermolysis in the

targeting of pigmented lesions. Melanosome destruction occurs at pulse durations between 40 and 750 nanoseconds. The efficacy of lasers used for the treatment of cutaneous pigmentation depends on the localization of the pigment (epidermal, dermal or mixed), the way it is packaged (intracellular or extracellular) and the nature of the pigment (melanin).<sup>3</sup> Between the wavelengths of 630 and 1100 nm there is both a preferential laser light absorption of melanin over hemoglobin as well as an effective laser dermal penetration.

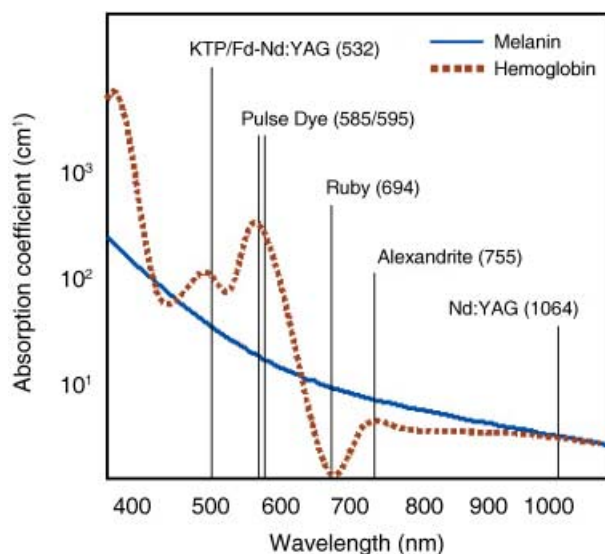
Melasma occurs due to a combination of genetic, sun-induced and hormonal factors; therefore successful laser treatment is the exception rather than the rule. Nevus of Ota responds very well to Q-switched laser treatment.<sup>4</sup> Café-au-lait macules respond to the Q switched lasers but have a tendency to recur.<sup>5,6</sup> Becker's nevi also show resolution after treatment, but recurrences are common.

## Green lasers

Due to their wavelength green light lasers can only penetrate the superficial papillary dermis and are therefore indicated for epidermal pigmented lesions.

Correspondence: David J. Goldberg, MD, JD, Skin Laser & Surgery Specialists of New York and New Jersey, 115 E. 57<sup>th</sup> Street, Suite 710, New York, NY, 10022 USA. E-mail: drdavidgoldberg@drdavidgoldberg.com

Accepted for publication March 19, 2006



**Figure 1** Melanin and hemoglobin absorption graph.

*Frequency doubled Q-switched Nd:YAG (neodymium:yttrium-aluminum-garnet) laser (532 nm, 5–10 ns)*

By placing crystals in the 1064 nm Nd:YAG (neodymium-yttrium-aluminum-garnet) laser beam's path, frequency-doubling halves the original 1064 nm wavelength to 532 nm. The frequency-doubled Nd:YAG laser is the shortest wavelength laser currently used for pigmented lesions. This laser produces excellent results when used to treat epidermal-pigmented lesions such as solar lentigines and ephelides. A recent study showed that the frequency-doubled Nd:YAG (532 nm) laser safely and effectively treats freckles and lentigines in Fitzpatrick skin type IV. Recurrence rates were low after the treatment of freckles and none after treatment for lentigines.<sup>7</sup> The degree of response to the laser at this wavelength is proportional to the amount of pigment chromophore present at the treatment site. When high fluences are delivered through small spot sizes, whitening of the skin is noted. This is then followed by pinpoint bleeding leading to a hemorrhagic crust. This crust falls off in 7–10 days.

*Other green lasers*

Nonpulsed, quasi-continuous wave green light lasers such as the copper vapor (511 nm), krypton (520–530 nm), and variable pulse with KTP (532 nm) lasers share some characteristics with the aforementioned nanosecond pulsed lasers. However, because the thermal relaxation time of the melanosome is exceeded using these lasers, there is an absence of reproducible spatial confinement of thermal injury. Such lasers do not produce the same consistent clinical results. The flash lamp-pumped pulsed dye laser (FLPDL) produces a 510-nm wavelength and

300 ns pulse of energy and produces excellent results when used to treat epidermal-pigmented lesions such as solar lentigines and ephelides, but in view of the purpura it caused, the use of the FLPDL for pigmented lesions has fallen out of favor.

**Red lasers**

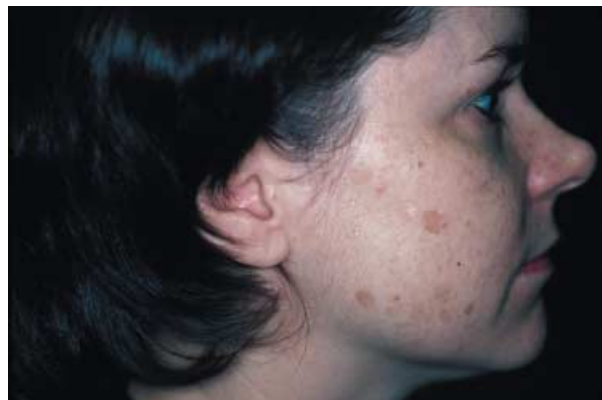The ruby and alexandrite lasers are well absorbed by melanin and penetrate sufficiently enough to be effective in the treatment of pigmented lesions at a deeper skin depth than the green lasers.

*Q-switched ruby laser (694 nm, 25–40 ns)*

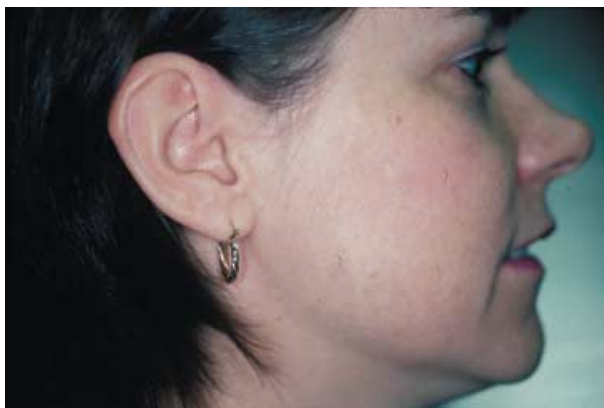The Q-switched ruby laser emits a 694 nm beam with a 20–40 ns pulse duration. Pigmented lesions are generally treated with a fluence of 4.0–6.0 J/cm<sup>2</sup>. Ruby laser light is well absorbed by melanin and is minimally absorbed by hemoglobin. Epidermal pigmented lesions such as lentigines and ephelides usually clear after one to four treatments. This laser can also completely remove flat (nonpalpable) acquired junctional melanocytic nevi with one to three treatment sessions, without any scarring or pigmentary disturbance.<sup>8</sup> Compound nevi do not respond.

The deeper penetration of the ruby laser means that it can be used for dermal pigmented lesions while avoiding vascular dermal structures. Among the benign pigmented lesions that respond well are ephelides, pigmented actinic keratosis, nevus of Ota and nevus of Ito.<sup>4</sup>

After Q-switched ruby laser treatment of nevus of Ota and nevus of Ito there is the histologic appearance of destroyed deep spindle cell-shaped dermal melanocytes.<sup>9</sup> Due to the greater melanin absorption, the risk of post-inflammatory hypopigmentation is higher with the ruby laser than that seen after treatment with the Q-switched alexandrite and Nd:YAG lasers (Figs 2, 3).



**Figure 2** Lentigines before treatment with the Q-switched ruby laser.



**Figure 3** Improvement in lentiginos after treatment with the Q-switched ruby laser.

#### *Q-switched alexandrite laser (755 nm, 50–100 ns)*

The Q-switched alexandrite laser is a solid state laser that emits a 755-nm wavelength with pulse durations of 50–100 ns and a fluence of 5.0–6.5 J/cm<sup>2</sup>. Since the wavelength and pulse duration is very similar to the Q-switched ruby laser the results from this laser are also somewhat similar. The longer wavelengths of this laser allow deeper penetration into the dermis. Nevus of Ota has been shown to be successfully treated by the Q-switched alexandrite laser without a high risk of side-effects.<sup>10</sup>

#### Near infrared lasers

##### *Q-switched Nd:YAG laser (1064 nm, 5–10 ns)*

The Q-switched Nd:YAG laser is generally operated at a fluence of 3–6 J/cm<sup>2</sup>. Melanin does not absorb the 1064 nm wavelength well, making the Nd:YAG's 1064 nm wavelength sub-optimal for the treatment of benign pigmented lesions. Despite less absorption by melanin at 1064 nm, the advantage of this laser lies in its ability to penetrate deeper into the skin (5–7 mm).<sup>11</sup> This laser may be more useful in the treatment of lesions in individuals with darker skin tones. Similarly to the Q-switched ruby and alexandrite lasers, the Q-switched Nd:YAG laser is highly effective in clearing nevus of Ota lesions. Histologically, the post-treatment findings at 1064 nm are identical to that of the Q-switched ruby laser. "Ring cells" representing vacuolated pigmented cells with peripheral condensation of pigment are detected in the epidermal basal cell layer.<sup>12</sup> Due to the deeper laser-induced penetration, patients experience more discomfort with this laser. The healing period may be slightly more prolonged than is seen with the ruby and alexandrite laser treatments.

#### Nonselective laser techniques – CO<sub>2</sub>/Er:YAG lasers

Epidermal pigmented lesions can also be treated with pigment nonselective lasers, such as the carbon dioxide laser (10 600 nm) and the erbium:YAG (2940 nm) laser. These ablative skin resurfacing lasers can also be used to remove superficial pigmented lesions.

#### Lasers for vascular lesions

The absorbing chromophore in the treatment of vascular lesions is hemoglobin in its various states. The major absorption peaks are 418, 542, and 577–595 nm. The 418 nm wavelength has the strongest absorption peak, but it is also simultaneously absorbed by melanin in the epidermis and therefore can cause post-treatment pigmentary changes. This makes the 577–595 nm wavelengths, which are less well absorbed by melanin, potentially more appropriate for targeting vascular lesions with less subsequent pigmentary alterations. For effective laser treatment the laser needs to penetrate to the depth of the target vessel. In addition laser exposure needs to be long enough to cause sufficient slow coagulation of the vessel.

The thermal relaxation time (TRT) of the treated vessel is dependent on the diameter of that vessel. The TRT of various size vessels can be calculated and the pulse duration of the utilized laser adjusted accordingly.<sup>13</sup>

#### Yellow lasers

##### *Pulsed dye laser (585–595 nm wavelength-varied pulse durations)*

The flash lamp pulsed dye laser (FLPDL) was the first laser developed based on the principles of selective photothermolysis.<sup>14</sup> It was specifically designed to treat cutaneous vascular lesions. The initial 577 nm wavelength, which corresponded with the second major absorption peak of oxyhemoglobin, was later changed to 585 nm. Current wavelengths also include 595 and 600 nm. These slightly longer wavelengths allow deeper penetration of the laser light up to a depth of approximately 1.2 mm. The FLPDL has as its active medium an organic dye energized by a short pulse of light from a flash lamp. The variable emitted pulse duration of 450 μs to 1.5 ms is shorter than the thermal relaxation time of the vessels that comprise most cutaneous vascular lesions.

The FLPDL is effective for treatment of telangiectases,<sup>15</sup> superficial strawberry hemangiomas, venous lakes, poikiloderma of Civatte, hypertrophic scars, flushing and diffuse erythema and remains the gold standard in the treatment of port wine stains.<sup>16</sup> A pulse stacking technique

may improve clinical results when treating telangiectasis without significantly increasing adverse effects.<sup>17</sup> Large spot size FLPDL treatment allows faster treatment. The disadvantage, when this laser is used with shorter pulse durations, is the postoperative purpura, which typically lasts 1–2 weeks after treatment. Occasional postinflammatory pigmentation, usually lasting 3–4 months, can be observed. It should be noted that these temporary complications can be cosmetically unacceptable to some patients. As a general rule this laser is safest in skin type's I–IV. For darker skin types melanin competes with hemoglobin for laser light absorption. This competition can also lead to a reduced clinical response and permanent hypopigmentation.

Newer higher energy, and longer pulse width, systems may lead to even better treatment of mature, nodular hypertrophic port wine stains, occasional haemangioma, and larger and/or deeper facial telangiectases (Figs 4, 5).

#### Green lasers

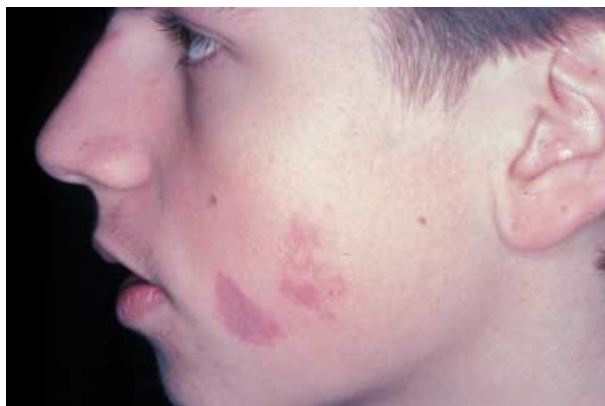##### *KTP laser (frequency-doubled Nd:YAG)*

The 532 nm green light laser wavelength is near the first absorption peak of hemoglobin. KTP lasers are currently very popular for the nonpurpuric treatment of facial telangiectases and rosacea.<sup>18</sup> KTP lasers' adjustable pulse width (1–50 ms) and spot sizes (1–6 mm) allow for the treatment of a variety of vascular lesions.

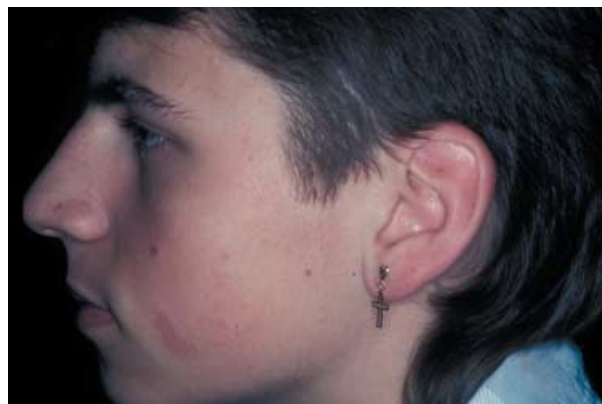#### Near infrared laser

##### *Nd:YAG laser*

The near-infrared 1064 nm Nd:YAG laser is also utilized for vascular lesion treatment. This wavelength is not as well absorbed by hemoglobin as the previously discussed



**Figure 4** Port wine stain before treatment with FLPDL.

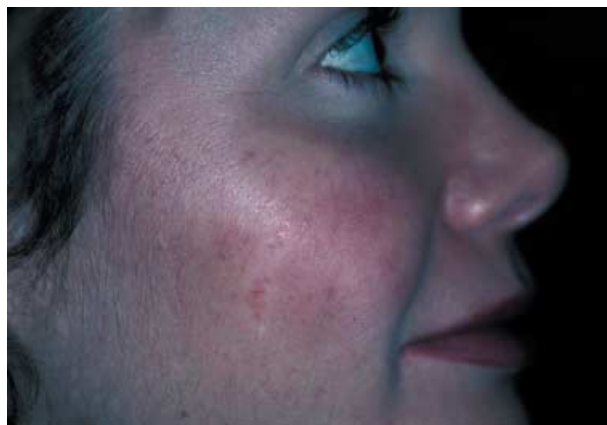

**Figure 5** Port wine stain after 8 FLPDL treatments.

green and yellow wavelength lasers, but there is almost no melanin competition at this longer wavelength. The longer wavelength leads to deeper penetration and targeting of deeper, blue spider veins of up to 3 mm.<sup>19</sup> One recent study compared the results of the long pulsed Nd:YAG laser treatment with sclerotherapy for small leg telangiectasias. The authors noted that the results were similar.<sup>20</sup> The results were further improved when these two modalities were combined. Postsclerotherapy-induced neovascular formation or matting is also effectively treated by the 1064 nm Nd:YAG laser.<sup>20</sup>

#### Treatment of pigmented and vascular lesions with a noncoherent light source – intense pulsed light

Intense pulsed light (IPL) systems are high-intensity light sources that emit polychromatic light. Unlike laser systems, these flash lamps work with noncoherent light in a broad wavelength spectrum of 500 nm to over 1100 nm at energies up to 80 J/cm<sup>2</sup>. Different wavelengths can be emitted using a variety of filters. These filters generally range between 515 and 590 nm with high cutoff filters protecting darker skin. The light can be delivered as single, double, or triple pulses in the millisecond range. These pulses protect the outer epidermis. These adjustable wavelengths and pulse durations allow this system to provide good diversity in the treatment of a variety of vascular<sup>21</sup> and pigmented lesions for different skin types. Light is delivered through a variable sized aperture which may contain a cooling device. Short-lived erythema is generally the only acute side effect noted. The range of therapeutic uses for high-intensity flash lamps includes the treatment of benign cavernous hemangiomas, benign venous malformations, essential facial telangiectasias, poikiloderma of Civatte, port wine stains and, to a lesser extent, leg telangiectasias. Because of the wide spectrum



**Figure 6** Facial erythema before treatment with an IPL.



**Figure 7** Facial erythema after 4 IPL treatments.

of potential combinations of wavelengths, pulse durations, pulse frequency, and fluences, a good deal of experience has been required when using older IPL technology. Proper patient selection helps to keep the adverse effects to a minimum and positive result to a maximum (Figs 6, 7).<sup>22</sup>

## Conclusion

Today's varied laser and light source technologies offer a wide variety of treatment options for the laser practitioner.<sup>23,24</sup> Some offer better results than others in the treatment of different pigmented and vascular lesions. However, there is, as yet, no single laser system that successfully treats all pigmented and vascular lesions; future technologies may introduce lasers that will be even more effective. Adjunctive treatments to laser- and light-based technologies include chemical peels, microdermabrasion, and topical agents such as retinoids. Practitioner education and patient safety remains the mainstay of successful treatment in the exciting field of lasers in dermatology.

## References

- Anderson R, Parrish J. The optics of human skin. *J Invest Dermatol* 1981; **77**: 13–9.
- Bashour M. (2003) *Laser hair removal* [WWW document]. URL <http://www.emedicine.com/ent/topic738.htm> (accessed 5 April 2004).
- Dierickx CC. Lasers in pigmentary disorders. *Pigment Cell Res* 2003; **16**: 590.
- Chan HH, Kono T. Nevus of Ota: clinical aspects and management. *Skinmed* 2003; **2**: 89–96; quiz 97–8.
- Alster TS. Complete elimination of large café-au-lait birthmarks by the 510 nm pulsed dye laser. *Plast Reconstr Surg* 1995; **96**: 1660–4.
- Alora MB, Arndt KA. Treatment of a cafe-au-lait macule with the erbium:YAG laser. *J Am Acad Dermatol*. 2001; **45**: 566–8.
- Rashid T, Hussain I, Haider M, Haroon TS. Laser therapy of freckles and lentigenes with quasi-continuous, frequency-doubled, Nd:YAG (532 nm) laser in Fitzpatrick skin type IV: a 24-month follow-up. *J Cosmet Laser Ther* 2002; **4**: 81–5.
- Westerhof W, Gamei M. Treatment of acquired junctional melanocytic naevi by Q-switched and normal mode ruby laser. *Br J Dermatol* 2003; **148**: 80–5.
- Goldberg D. Benign pigmented lesions of the skin: treatment with the Q-switched ruby laser. *J Dermatol Surg Oncol* 1993; **19**: 376–9.
- Alster TS, Williams CM. Treatment of nevus of Ota by the Q-switched alexandrite laser. *Dermatol Surg* 1995; **21**: 592–6.
- Goldberg DJ. Treatment of pigmented and vascular lesions of the skin with the Q-switched Nd:YAG laser (abstract). *Lasers Surg Med* 1993; **13**: 55.
- Kilmer SL, Wheeland RG, Goldberg DJ *et al*. Treatment of epidermal pigmented lesions with the frequency-doubled Q-switched Nd: YAG laser: a controlled, single-impact, dose–response, multicenter trial. *Arch Dermatol* 1994; **130**: 1515–9.
- Lowe NJ, Carruthers A, Carruthers J *et al*. *Textbook of Facial Rejuvenation*. London: Martin Dunitz; 2002: p. 86.
- Garden JM, Polla LL, Tan OT. Treatment of port wine stains by the pulsed dye laser. Analysis of pulse duration and long term therapy. *Arch Dermatol* 1988; **124**: 896.
- Kauvar AN, Frew KE, Friedman PM, Geronemus RG. Cooling gel improves pulsed KTP laser treatment of facial telangiectasia. *Lasers Surg Med* 2002; **30**: 149–53.
- Dierickx CC. Lasers in pigmentary disorders. *J Eur Acad Dermatol Venereol* 2001; **15**: 388.
- Rohrer TE, Chatrath V, Iyengar V. Does pulse stacking improve the results of treatment with variable-pulse pulsed-dye lasers? *Dermatol Surg* 2004; **30**: 163–7.
- Bassichis BA, Swamy R, Dayan SH. Use of the KTP laser in the treatment of rosacea and solar lentigenes. *Facial Plast Surg* 2004; **20**: 77–83.
- Levy JL, Elbahr C, Jouve E *et al*. Comparison and sequential study of long pulsed Nd:YAG 1064 nm laser and sclerotherapy in leg telangiectasias treatment. *Lasers Surg Med* 2004; **34**: 273–6.

- 20 Raskin B, Fany RR. Laser treatment for neovascular formation. *Lasers Surg Med* 2004; **34**: 189–92.
- 21 Angermeier MC. Treatment of facial vascular lesions with intense pulsed light. *J Cutan Laser Ther* 1999; **1**: 95–100.
- 22 Raulin C, Greve B, Grema H. IPL technology: a review. *Lasers Surg Med* 2003; **32**: 78–87.
- 23 Goldberg DJ. Laser treatment of pigmented lesions. In: T Alster, D Apfelburg, eds. *Cosmetic Laser Surgery*. Wiley-Liss, 1998.
- 24 Goldberg DJ. Laser treatment of pigmented lesions and tattoos. In: R Narins, ed. *Cosmetic Dermatologic Surgery*. New York: Marcel Dekker, Inc.; 2000.