

ORIGINAL ARTICLE

## Acne scar correction using calcium hydroxylapatite in a carrier-based gel

DAVID J. GOLDBERG<sup>1,2</sup>, SNEHAL AMIN<sup>1</sup> & MUSSARRAT HUSSAIN<sup>1</sup>

<sup>1</sup>Skin Laser & Surgery Specialists of New York/New Jersey, New York, NY, USA, and <sup>2</sup>Mount Sinai School of Medicine, New York, NY, USA

### Abstract

**Objectives:** This study sought to determine the efficacy and safety profile of calcium hydroxylapatite filler in the treatment of acne scars. **Methods:** Ten subjects with a variety of acne scars were treated with calcium hydroxylapatite filler. **Results:** Saucerized acne scars responded to treatment; ice-pick scars did not. Results lasted, at least to some degree, for 12 months after treatment. No significant treatment complications were noted. **Conclusions:** Calcium hydroxylapatite is a safe and effective long-term filler for the treatment of saucerized acne scars.

**Key words:** Calcium hydroxylapatite, acne scars, dermal fillers

### Introduction

Acne remains a common dermatologic problem, affecting up to 80% of people between 11 and 30 years of age and up to 5% of older adults (1). Acne scarring has been variously described and classified, with the terms ice-pick scars, rolling scars, and boxcar scars used to describe forms of atrophic scarring resulting from tissue loss (1,2). Individuals often present with a mixed pattern of scarring. Hypertrophic and keloidal acne scarring is significantly less common than atrophic scarring, and requires different correction strategies (2).

Many patients, despite resolution of active acne, remain marked with residual scarring. Factors that contribute to the degree, extent, and morphology of scarring are multiple. They include the severity and duration of acne as well as individual patient characteristics. Several surgical and non-surgical options (e.g. punch excision, punch grafting, subcutaneous incision (subcision), and laser resurfacing) are available for ameliorating the appearance of acne scarring. The choice of option depends on the scar morphology and degree and extent of scarring, as well as the patient's skin type. Many patients benefit from a combination of strategies (2).

Soft tissue fillers may also play a role in the treatment of acne scarring (1–3). Soft tissue fillers

are presently used for a myriad of facial contouring and augmentation applications, including augmentation of nasolabial folds and marionette lines, pre-jowl depressions, nasal contouring, and correction of acne scars (2–5). Soft tissue fillers may be particularly attractive for acne scarring because they permit simple and exact non-surgical correction of scars, either when used independently or in conjunction with other techniques (2,3).

The ideal filler for this purpose would be long-lasting, biocompatible, and would not elicit further inflammation or granuloma formation in skin already damaged by acne. The injectable soft tissue filler calcium hydroxylapatite (CaHA) is a durable, biocompatible, soft tissue filler that is well-suited for use in acne scar correction. This study evaluated the safety and efficacy of CaHA injections in the treatment of acne scarring.

### Methods

Ten subjects with acne scarring were treated in a single-center, prospective, controlled trial. All subjects had at least one saucerized acne-induced scar and ranged in age from 18 to 60 years of age. Subjects were excluded from the study for one or more of these criteria: had any known bleeding

disorders, were on any anticoagulants/anti-inflammatory agents from 1 week before to 1 month after CaHA injections, had received collagen and/or hyaluronic acid injections to treated areas within 6 months of the study, had ever received silicone injections to their acne scars, and/or were using any 'wrinkle' treatment products within 4 weeks before or during the study.

CaHA (Radiesse™; Bioform Medical, San Mateo, CA, USA) was injected through a 27-gauge needle into the mid to deep dermis of the treated acne scars. The volume of injection was recorded for each subject. All subjects were seen at 1, 2, 3, 6 and 12 months after treatment. At the 1-month visit, more CaHA was injected if the treating physician determined that benefit would be obtained. Efficacy was determined at 12 months after the initial injection.

Twelve-month efficacy results were determined by an independent non-treating physician, based on evaluation of ice-pick and saucerized scars using a 1–5 rating system (1=no change; 2=<25% improvement; 3=<50% improvement; 4=<75% improvement; 5=>75% improvement). All evaluations, from 1 month to 12 months, included signs and symptoms of the following adverse reactions: echymosis, edema, erosion, erythema, extrusion, hematoma, infection, and nodule and further scar formation.

## Results

Total volumes used ranged from 0.1 to 0.3 ml CaHA per treatment. At the 12-month evaluation, three subjects showed >75% improvement; six subjects showed between 50% and 75% improvement, and one subject showed between 25% and 50% improvement in treated saucerized scars (Figures 1 and 2). No subjects showed any improvement in their ice-pick scars (Figures 3 and 4). One subject showed some persistent erythema at one treated site at the 1-month evaluation. This was resolved by the 2-month visit. Extrusion at the injection site was noted in four subjects. Three subjects received a

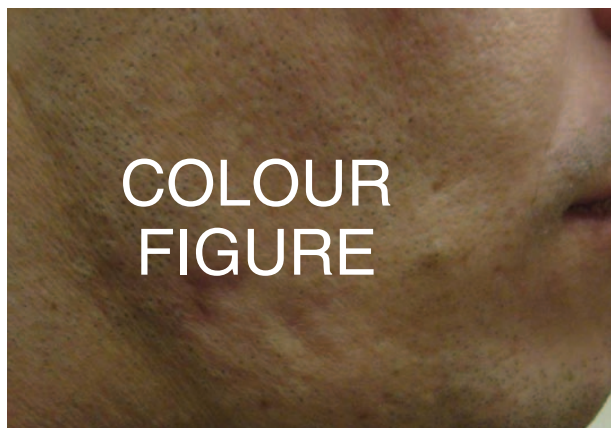

Figure 1. Saucerized acne scars before treatment.

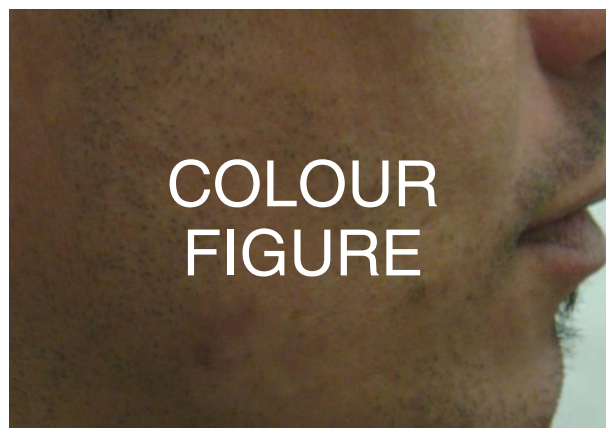

Figure 2. More than 75% improvement in acne scars 12 months after treatment.



Figure 3. Ice-pick acne scars.




Figure 4. No improvement in ice-pick acne scars 12 months after treatment.

second treatment 1 month after the first series of injections.

## Discussion

Calcium hydroxylapatite is a synthetic compound composed of calcium and phosphate ions, identical

to the mineral portion of bone and teeth, and metabolized similarly to the natural compound. The Radiesse brand of CaHA is an injectable filler material composed of CaHA microspheres (25–45  $\mu\text{m}$ ) suspended in an aqueous carboxymethylcellulose carrier gel. The ingredients of the aqueous gel carrier – cellulose, glycerin, and sterile water – are classified as ‘generally recognized as safe’ by the Food and Drug Administration (6).

Following injection, the gel carrier is gradually absorbed and replaced by surrounding fibroblasts, with the CaHA particles forming a ‘scaffold’ for tissue formation and deposition of collagen. Through this process, the injected material is effectively fixed into place, helping to prevent migration (6). The result is a long-lasting, but semi-permanent, implant of CaHA particles and natural tissue.

In vivo and in vitro studies have established the biocompatibility and safety of CaHA. In a study of dermal biopsies analyzed by histopathology and electron microscopy at 1 month and 6 months post-injection, researchers noted the persistence of CaHA particles, with evidence of new extracellular matrix formation. No evidence of granuloma formation, ossification, or foreign body reactions was found (7). In long-term animal studies, CaHA implants have persisted intact at the injection site throughout the 3-year study period (6). In vivo, durability varies somewhat depending on the injection site, patient age, and relative rates of metabolism, with longevity in areas such as the face reported as being up to 12–18 months and in the bladder as up to 3 years (8).

In the USA, CaHA is presently FDA-cleared for use in injectable form for oral/maxillofacial defects, vocal fold augmentation, and as a radiographic tissue marker. In addition, CaHA has been approved for stress urinary incontinence in a formulation with larger microspheres than that used for skin soft tissue defects. CaHA has also been used off-label in the USA for a variety of aesthetic applications, including augmentation of the nasolabial

folds, HIV-associated facial lipoatrophy, marionette lines, pre-jowl sulcus, malar eminence and submalar hollowing, and depressed scars (including acne scars) for nearly 4 years (4,8–13).

Our study documents the efficacy of CaHA in the treatment of saucerized acne scars. Although improvement was noted in all individuals at 12 months, the duration of cosmetic benefit may be even longer. Additional studies should provide better insight into the longevity of the result.

## References

1. Jacob CI, Dover JS, Kaminer MS. Acne scarring: a classification system and review of treatment options. *J Am Acad Dermatol.* 2001;45:109–107.
2. Goodman GJ. Post acne scarring: a review. *J Cosmetic & Laser Ther.* 2003;5:77–95.
3. Jemec GB, Jemec B. Acne: treatment of scars. *Clinics in Dermatol.* 2004;22:434–438.
4. Tzikas TL. Evaluation of the Radianse FN soft tissue filler for facial soft tissue augmentation. *Arch Facial Plast Surg.* 2004;6:234–239.
5. Kanchawala SK, Holloway L, Bucky LP. Reliable soft tissue augmentation: a clinical comparison of injectable soft-tissue fillers for facial volume-augmentation. *Ann Plast Surg.* 2005;55:30–35.
6. Hubbard W. *BioForm Implants: Biocompatibility.* Franksville, WI. 2003.
7. Marmur ES, Phelps R, Goldberg DJ. Clinical, histologic, and electron microscopic findings after injection of a calcium hydroxyapatite filler. *J Cosmet Laser Ther.* 2004;6:223–226.
8. Ditre CM. Aesthetic considerations in the treatment of facial lipoatrophy. *Cosmetic Dermatol.* 2006;19(2):9–11[S1].
9. Felderman LI. Radiesse™ for facial rejuvenation. *Cosmetic Dermatol.* 2005;18(12):823–826.
10. Silvers SL, Eviatar JA, Echavez MI, Pappas AL. Prospective open label 12-month trial of calcium hydroxylapatite (Radiesse) for facial soft tissue augmentation in patients with HIV-associated lipoatrophy. *Plast Recon Surg.* 2006 (in press).
11. Sklar JA, White SM. Radianse FN: a new soft tissue filler. *Dermatol Surg.* 2004;30:764–768.
12. Flaharty P. Radianse FN for facial plastic soft tissue filling. *Facial Plast Surg.* 2004;20(2):165–169.
13. Comite SL, Liu JF, Balasubramanian S, Christian MA. Treatment of HIV-associated facial lipoatrophy with Radianse FN (Radiesse). *Dermatol Online J.* 2004;10(2).